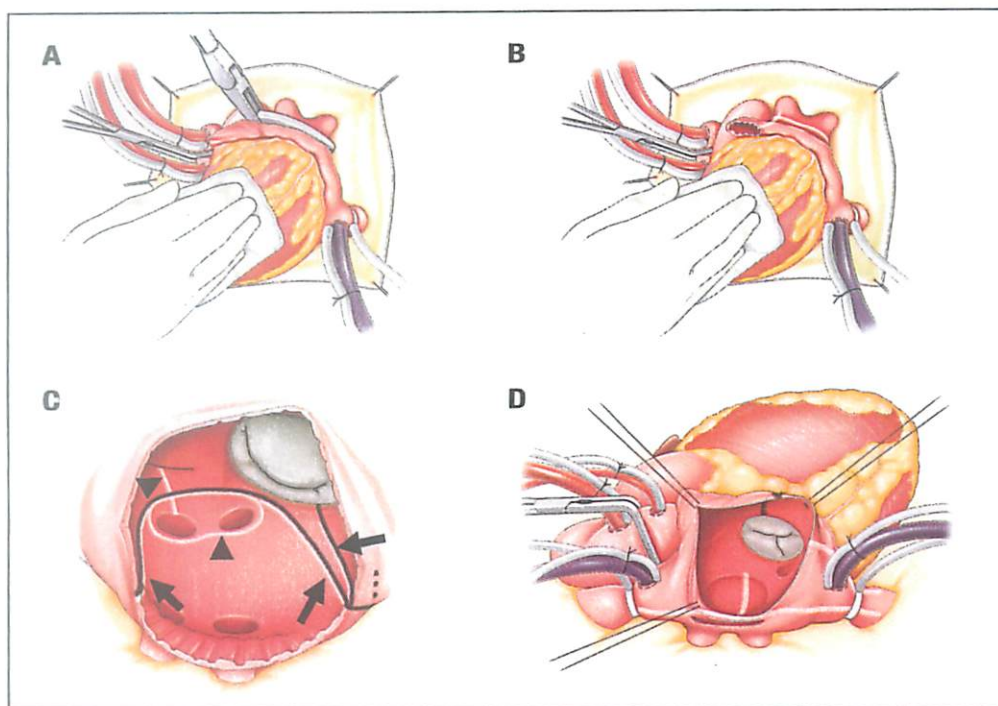


THE ANNALS OF THORACIC SURGERY

Volume 109 ■ Number 3 ■ March 2020



Cox maze IV procedure followed in the study. Pulmonary vein (PV) isolation using bipolar radiofrequency clamp (A). Appendage amputation and ablation toward PV (B). Lesions from the lateral side (white line with black arrowheads), bipolar clamp PV isolation (white line with black arrows), and cryoablation (black lines, C). Bipolar clamp ablation (white lines) and tricuspid lesion (black line, D).

From Takagaki et al in this issue, p. 773.



OFFICIAL JOURNAL OF
THE SOCIETY OF THORACIC SURGEONS
AND THE SOUTHERN THORACIC SURGICAL ASSOCIATION

ELSEVIER
ISSN 0003-4975

